

East of England Neonatal Neuroprotection Regional Guideline for Cerebral Function Monitoring of Neonates

Clinical Guideline:

Authors: Topun Austin, Claudia Chetcuti-Ganado and Neuroprotection steering group

For use in: EoE Neonatal Units
Guidance specific to the care of neonatal patients.

Date of Ratification: **March 2022**

Review due: **March 2025**

Registration No: **NEO-ODN-2022-5**

Approved by:

| | |
|--------------------------------------|----------------------|
| Neonatal Clinical Oversight Group | |
| Clinical Lead Matthew James | Matthew James |

East of England Neonatal Neuroprotection

AUDIT STANDARDS:

1. The CFM should be attached *only* by personnel who have been trained in its application to infants.
2. The procedure is fully documented

CONTENTS:

1. **Objective of guideline**
2. **Summary of guidelines**
 - 2.1 Which infants should be monitored
 - 2.2 When should imaging be commenced
 - 2.3 Who should attach the cerebral function monitor
 - 2.4 Attachment of the cerebral function monitor
 - 2.5 Interpretation of the cerebral function monitor tracing
 - 2.6 Documentation
 - 2.7 For how long should aEEG monitoring be continued
3. **Rationale for the recommendation**
 - 3.1 aEEG and association with neurodevelopmental outcome
 - 3.2 Use of cerebral function monitoring to refine prediction of prognosis in Hypoxic-Ischaemic Encephalopathy
 - 3.3 Role of aEEG in therapeutic hypothermia
 - 3.4 Note of comparison if aEEG with standard 12-lead EEG
4. **Role of the CFM in preterm infants**
5. **References**

Appendix 1-Cerebral Function Monitoring Observation Chart

Appendix 2 – Cerebral Function Monitoring Clinical Competency Checklist

Appendix 3- Cerebral Function Monitoring of Neonates Report Sheet

Regional Guideline for Cerebral Function Monitoring of Neonates

1. Objective of Guideline

- To define which infants should routinely undergo continuous amplitude-integrated EEG (aEEG) monitoring during neonatal intensive care.
- To facilitate prompt cerebral function monitoring of these infants.
- To provide information on prognosis that can be obtained from aEEG trace in the early neonatal period.

2. Summary of Guideline

2.1 WHICH INFANTS SHOULD BE MONITORED?

i) Term/ near term Infants

Cerebral Function Monitoring (CFM) should routinely be used for all infants of gestational age ≥ 36 weeks who have one or more of the following:

- a) Evidence of possible hypoxic-ischaemic encephalopathy (HIE) who meet A and B criteria inline with the [EoE HIE guideline](#).
- b) Seizures, definite or possible.
- c) Infants receiving muscle relaxants where neurological assessment is not possible.

ii) CFM may also provide useful information in:

- Meningitis (requiring intensive care).
- Evidence of extensive structural brain injury or serious congenital brain anomalies (e.g cerebral infarction, congenital brain haemorrhage/ tumour, hydrocephalus).

iii) Preterm Infants

The CFM may be less easy to interpret in preterm infants. Nevertheless, it can provide very useful information and so may be considered in some infants of ≤ 36 weeks' gestation, e.g

- Clinical or suspected seizures.
- Encephalopathy.
- Grade 3 or 4 intraventricular haemorrhage.

CFM of preterm infants should be at the discretion of the attending consultant

2.2 WHEN SHOULD MONITORING BE COMMENCED?

- Apply the CFM as soon as possible to at-risk infants in whom there are any neurological concerns.
- Apply as soon as possible following admission to the NICU of any infant with suspected hypoxic-ischaemic encephalopathy.
- Early application will help facilitate a reliable baseline.

East of England Neonatal Neuroprotection

2.3 WHO SHOULD ATTACH THE CEREBRAL FUNCTION MONITOR?

- The CFM should be attached *only* by personnel who have been trained in its application to infants.
- The attendant nurses and medical staff should record events that occur during the period of monitoring by entering details into the monitor: e.g. suctioning, X-ray, reintubation, and episodes of overt/possible seizures. This will facilitate proper retrospective interpretation of the traces and help distinguish artefact.

2.4 ATTACHMENT OF THE CEREBRAL FUNCTION MONITOR

See specific instrument guide for details.

Either standard EEG electrodes, gel electrode sets, cup electrodes, or disposable subdermal needle electrodes should be used to attach the CFM to the infant. Attention should be paid to correct placement of the electrodes on the head – particularly for dual channel monitoring. Lead attachment requires time, patience, and careful skin preparation and is a skill that must be learnt. Care must be taken when using subdermal needle electrodes in order to avoid/minimise:

- Pain on insertion
- Potential risk of infection to the baby.
- Risk of needle stick injury for staff.
- Risk of the needle electrode puncturing cooling wraps/mattresses in infants undergoing therapeutic hypothermia.

Needle electrodes should not be used if there is evidence of clotting abnormalities or active bleeding.

2.5 INTERPRETATION OF THE CEREBRAL FUNCTION MONITOR TRACING

Please note a free online course on interpretation of Cerebral Function application, monitoring and tracing developed by the Luton and Dunstable Neuroprotection team can be found through visiting the [BAPM website](#).

There are 3 parameters that can be measured by a Cerebral Function Monitor (CFM), all of which should be taken into consideration when interpreting and reporting. They are as follows:

1. **Impedance**, which is a measure of the electrical signal's conductivity, will tell you how good the contact is between the electrode and the scalp. It is essential to have good contact with low impedance. Loss of contact can increase artefact in the amplitude-integrated EEG (aEEG) trace making it impossible to be confident in its accuracy. It is not advisable to make decisions around treatment based on an aEEG trace with high impedance. Impedance is measured in Ohms (Ω). $<5\Omega$ is very good and $5-10\Omega$ is acceptable. If it is $>10\Omega$ efforts should be made to reduce this and the corresponding aEEG trace should be ignored. When reporting the aEEG the impedance should be documented as part of this.
2. **Raw-EEG**, this is the raw electrical signal measured directly from the electrodes before it is rectified and compressed by the monitor into the aEEG trace. It is important to inspect this when reporting as it helps to identify

East of England Neonatal Neuroprotection

seizures and artefact, and to differentiate between the different background patterns.

3. **Amplitude-integrated EEG (aEEG)** is the rectified and compressed trace that the monitor makes from the raw-EEG. By compressing the EEG to 1hr/6cms, the aEEG gives information on cerebral function and this can be assessed by looking at its characteristics as outlined in the following paragraphs.

There are currently two classifications/descriptions of amplitude-integrated EEG (aEEG) background pattern in use. They are as follows:

- 1) The study of al Naqeeb et al. ^[1], empirically classified the aEEG patterns into one of 3 categories (**Table 1**):

Table 1: A simple aEEG classification according to bandwidth voltage

| <i>Classification</i> | <i>Bandwidth Limits</i> |
|----------------------------|--|
| Normal | Lower limit >5µV and upper limit >10µV |
| Moderately abnormal | Lower limit <5µV and upper limit >10µV |
| Severely abnormal | Lower limit <5µV and upper limit <10µV |

- 2) The aEEG pattern descriptions used in the study of Toet *et al.* ^[2] were as follows:

- **Continuous normal voltage with cycling of sleep stages.** Continuous background activity with voltage 10–25 (–50) µV, with the band of aEEG activity altering in width, indicating cycling of sleep stages.
- **Continuous normal voltage.** Continuous background activity, voltage 10–25 (–50) µV but without sleep stages.
- **Discontinuous normal voltage.** Discontinuous trace, voltage predominantly >5 µV.
- **Burst suppression.** Discontinuous trace with periods of very low cortical activity (<5 µV), intermixed with bursts of higher amplitude. **[severely abnormal]**
- **Continuous low voltage.** Continuous background pattern of very low voltage (around or below 5 µV). **[severely abnormal]**
- **Flat tracing.** Mainly inactive (isoelectric tracing) of extremely low voltage (<5 µV). **[severely abnormal]**
- **Epileptic activity** may also identified by single or repetitive events (at a frequency of less than once per hour), with sudden sustained cortical activity.
- **Status epilepticus** is indicated by repeated epileptic activity, resulting in a regular pattern of increased cortical activity (sawtooth pattern).

Examples of these pattern descriptions are found in **Table 2**.

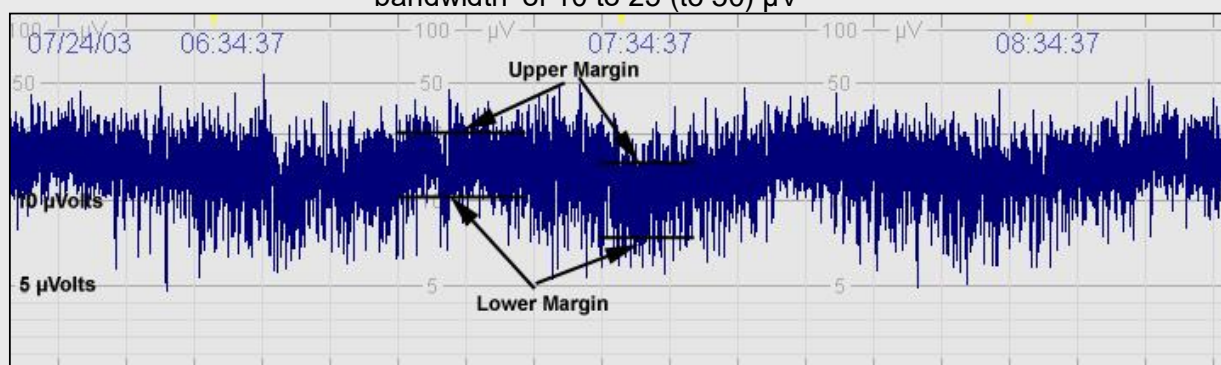
Table 2: A classification of aEEG patterns for preterm and term infants (from Hellström-Westas *et al.*, 2006 ^[3])

East of England Neonatal Neuroprotection

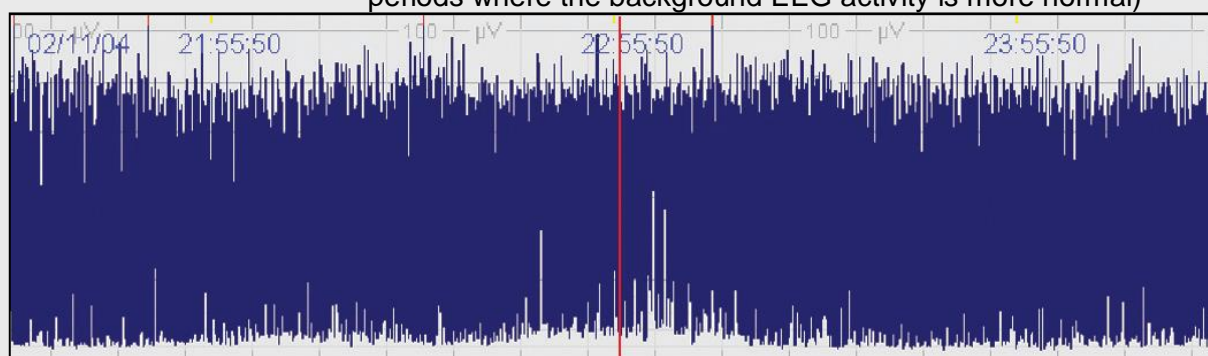
1. BACKGROUND PATTERN

Describes the dominating type of electrocortical activity in the aEEG trace.

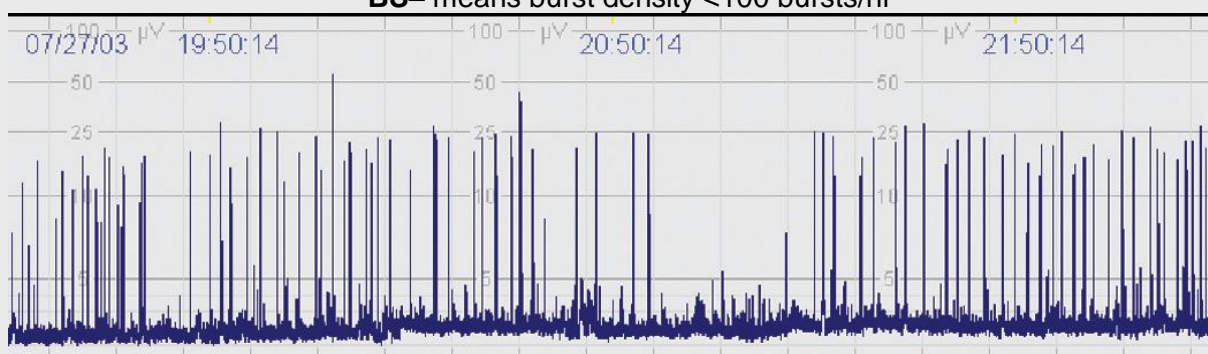
- Continuous (C):** Continuous activity with lower (minimum) amplitude of the 'bandwidth' around (5 to) 7 to 10 μV and maximum amplitude of the 'bandwidth' of 10 to 25 (to 50) μV



- Discontinuous (DC):** Discontinuous background with minimum amplitude variable, but below 5 μV , and maximum amplitude above 10 μV . ("Discontinuous" refers to a raw EEG appearance where there are alternating periods of relative inactivity/ low voltage interspersed with periods where the background EEG activity is more normal)



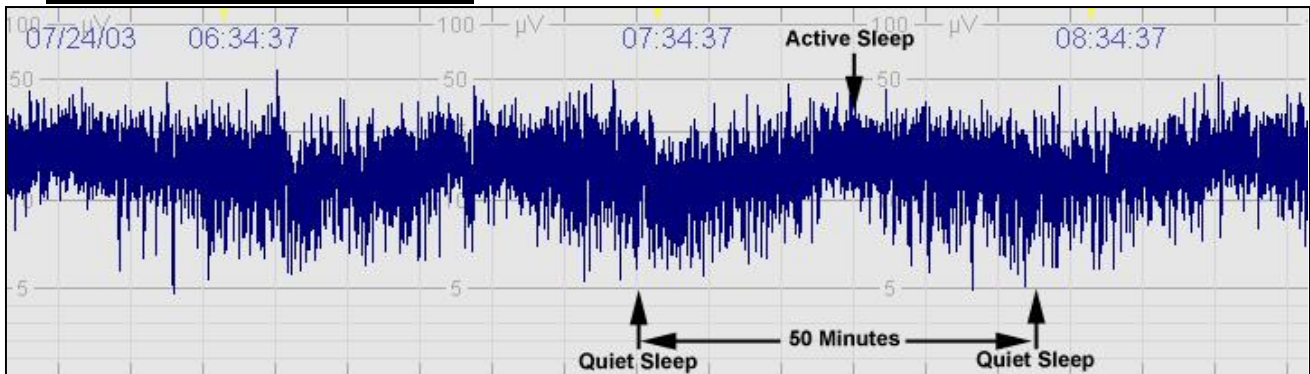- Burst suppression (BS):** Discontinuous background with minimum amplitude without variability at 0 to 1 (2) μV but with 2-3 second long bursts of amplitude $>25 \mu\text{V}$
BS+ denotes burst density >100 bursts/hr
BS- means burst density <100 bursts/hr



- Low voltage (LV):** Continuous background pattern of very low voltage (around or $<5 \mu\text{V}$)
- Inactive/ flat trace (FT):** Primarily inactive (isoelectric tracing) background below 5 μV

East of England Neonatal Neuroprotection

2. SLEEP-WAKE CYCLING

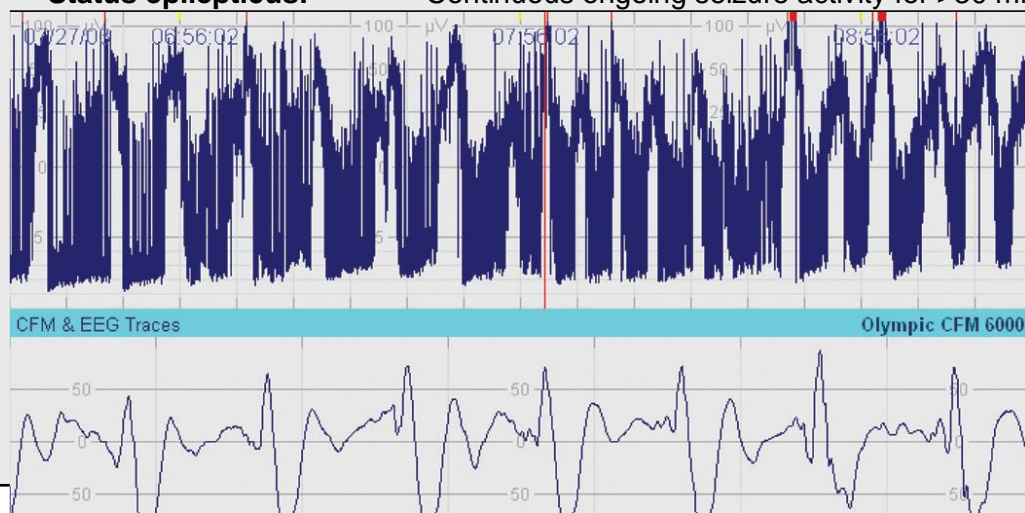

- **Sleep-wake cycling (SWC)** A normal finding in the aEEG. Characterized by smooth sinusoidal variations, mostly in the minimum amplitude. Broader bandwidth represents discontinuous background activity during quiet sleep, and narrower bandwidth corresponds to the more continuous activity during wakefulness and active sleep
- **No SWC:** No cyclic variation of the aEEG background
- **Imminent/immature SWC:** Some, but not fully developed, cyclical variation of the lower amplitude; not developed as compared with normative gestational age-representative traces
- **Developed SWC:** Clearly identifiable sinusoidal variations between discontinuous and more continuous background activity, with cycle duration >20 mins

3. SEIZURES

Epileptic seizure activity is usually seen in the aEEG as an abrupt rise in the minimum amplitude and a simultaneous rise in the maximum amplitude, often followed by a short period of decreased amplitude. The raw EEG should show simultaneous seizure activity, with a gradual build-up of high amplitude waves and then decline in frequency and amplitude of repetitive spikes or sharp-wave or activity with duration of at least 5 to 10 sec.

- **Single seizure:** A solitary seizure
- **Repetitive seizures:** Single seizures appearing more frequently than at 30 min intervals
- **Status epilepticus:** Continuous ongoing seizure activity for >30 minutes.



East of England Neonatal Neuroprotection

Although this guideline outlines both classification methods, there is a move to use the latter and more descriptive classification. Not only is it more descriptive, but can be used for infants of all gestations rather than just those that are near term. It also uses EEG terminology which provides more synergy between the two monitoring techniques.

2.6 ARTEFACT

It is important to identify any areas of trace with artefact and discount these areas from any decision making regarding plan of care or treatment. As with all reporting, inspecting the impedance and raw-EEG will help in determining areas of artefact.

Artefacts on aEEG together with the difficulty in interpreting raw EEG on CFM monitors, can be misdiagnosed as seizures. On aEEG the presence of seizures is shown by increased lower and upper amplitude and narrowing of bandwidth. The raw EEG may confirm seizures by showing the repetitive rhythmic spike and wave discharges. However, at times, it can show rhythmic slow activity that could be due to respiratory artefact. In the absence of typical changes on raw EEG a standard EEG should be organised.

Electrographic artefact may also lead to a 'drift of the baseline' effect in which the baseline tracing becomes falsely elevated in the setting of a severely suppressed background activity. A baseline level above $5\mu\text{V}$ may be mistaken for a more reassuring pattern. A clue to the presence of ECG artefact in the presence of a suppressed background, as opposed to seizures is that the rhythmic activity does not change in frequency or size.

Figure 1a

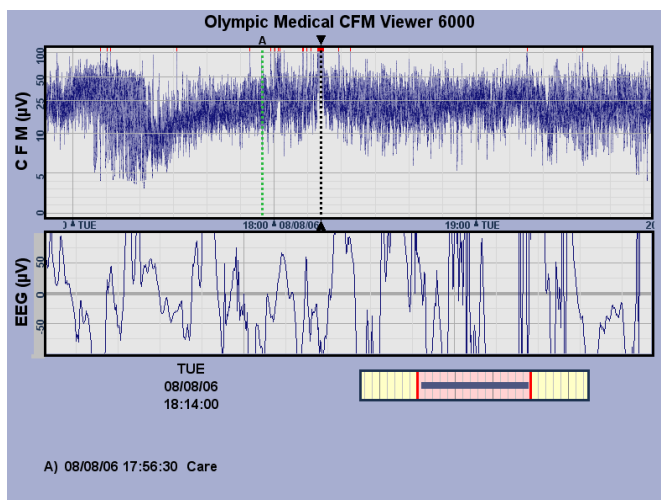


Figure 1a: General movement or loss of contact will result in a disorganised appearance of the raw-EEG with a huge variance in voltage. Note the sudden short peak in voltage in the aEEG trace (see dashed black line) that could be suggestive of a seizure if you didn't inspect the raw-EEG.

East of England Neonatal Neuroprotection

Figure 1b

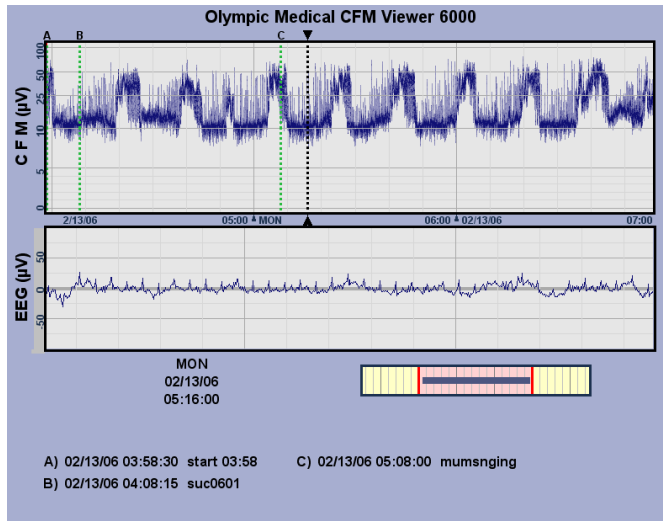


Figure 1b: Other electrical signals, such as ECG, can also be picked up by the CFM. This is especially so if the background voltage of brain activity is low or isoelectric, but this can also happen if the electrode is sitting directly over a scalp vessel. In this example, you can see the raw-EEG shows a regular pattern that doesn't evolve in its morphology. This suggests it is an ECG signal. Notice how it elevates the background aEEG trace to just above 10 microvolts. The aEEG background is very narrow with little continuity and no sleep wake cycling. This suggests it is a continuous low voltage trace but it is sitting at an abnormally high voltage.

Figure 1c

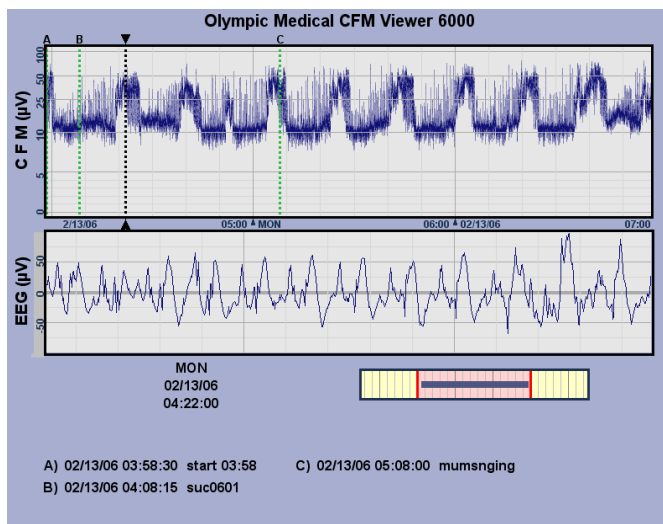


Figure 1c: This is taken from the previous trace, however in this example the raw-EEG corresponds to the peaks of the aEEG trace (see the dashed black line). Note the spikey electrical discharge on the raw-EEG that shows some evolution of voltage and morphology that is suggestive of seizures. It shows that although artefact, like ECG, can elevate the overall background aEEG trace we should always be vigilant for seizures. This aEEG shows multiple seizures.

East of England Neonatal Neuroprotection

Figure 2 (a) upper panel: aEEG background is continuous normal voltage aEEG with absent SWC and recurrent seizures; lower panel: a few seconds of single channel EEG at time point marked with the dotted line showing repetitive, rhythmical spike wave patterns indicative of epileptic seizures. Comment: the aEEG reveals a number of episodes of seizure activity where the amplitude increases and bandwidth narrows. (b) upper panel: aEEG background shows continuous low voltage, no SWC and the aEEG looks like recurrent seizures; lower panel: a few seconds of raw EEG at the point marked with the dotted line showing slow wave activity. Comment: the initial aEEG has a low voltage appearance that is then interrupted but surges in overall amplitude (but still with a narrow aEEG band) that look like seizures. The raw EEG does not show typical pattern, but slow activity that could be respiratory artefact. This is an example where standard EEG should be performed to confirm seizure activity. (c) upper panel: aEEG background is of low voltage but the surges in amplitude are so frequent this becomes difficult to appreciate. SWC is absent and status epilepticus is noted; lower panel: a few seconds of single channel EEG at time point marked with the dotted line showing rhythmical slow waves in the delta range. Comment: the aEEG trace has the rhythmical, repetitive saw tooth appearance consistent with status epilepticus but again the raw EEG does not show typical features of seizures, highlighting that the raw EEG can be confusing at times. ***Where doubt exists, standard EEG should be organized.***¹⁴

Figure 3 (a) upper panel: aEEG background shows low voltage continuous trace with possible superimposed bursts. No SWC is seen. Towards the right of the trace, the band moves upwards. A clinician could assume this is seizure activity or artefact; lower panel: a few seconds of single channel EEG at time point marked with the dotted line. Regular discharges can be seen throughout the window without any change in frequency or size. Comment: this recording is contaminated with artefact. Given the rhythmicity and frequency of the discharges on the raw EEG, this probably arising from the ECG/heart. The bursts of activity in the upper panel probably reflect this artefact, otherwise the aEEG is likely to be flat. (b) upper panel: aEEG background shows periods of continuous and discontinuous activity. SWC is present and no seizures are present; lower panel: a few seconds of single channel EEG at time point marked with the dotted line displaying rhythmical discharges which do not alter in anyway. Comment: careful inspection of all the information on the monitor reveals that, at the point of potential concern, the electrode impedance dramatically changes, just after 11.00 hours. The trace then becomes affected by artefact. It would be possible for an inexperienced operator to misdiagnose the raw EEG seizure activity, highlighting the need for adequate training¹⁴

Most cerebral function monitors have an event marking function. This should be utilised for all episodes of care and any episodes of abnormal movements. By doing this you can highlight areas for potential artefact or seizures and for review of the corresponding impedance and raw-EEG.

2.7 EFFECT OF DRUGS ON THE aEEG

Administration of morphine, phenobarbitone, lidocaine and midazolam may depress aEEG activity. A loading dose of phenobarbitone (10-20mg) may result in moderate depression of background activity. If phenobarbitone loading results in severe depression of the CFM background this may be a sign of more severely compromised cerebral function. Other factors that have been described to cause transient depression of aEEG include hypoglycaemia and pneumothorax. In preterm infants surfactant administration may result in a transient aEEG depression for about

10 minutes.³

2.8 DOCUMENTATION

The EoE recommends using a CFM observation chart for monitoring aEEG tracing. The observation chart included in Appendix 1 was shared by Luton and Dunstable Neuroprotection team. This chart-, developed as a Quality improvement initiative, has been found to greatly improve aEEG documentation and staff confidence in interpretation of tracing. A training course to accompany this chart is now available on bridge the EoE blended learning platform together with a competency checklist in Appendix 2.

It is still recommended that the clinician attending the infant and reviewing the aEEG tracing should make a written entry into the infant's case notes regarding their impression of the tracing. The tracings should be reviewed at each ward round and a full written report of the findings should be made 1 hour into recording (to establish background trace) at 6, 24, 48 hours and on rewarming as the findings on CFM at these time points have important prognostic implications (See Table 4). Full medical review and reporting of CFM should also occur when there are changes to the CFM background or limits within the amber or red observation chart zones, or any suspicion of seizures both clinical or electrographic See chart in appendix 3. Documentation should include whether there was artefact, antiepileptic drugs or sedative medications as these can affect the EEG tracing making interpretation for prognosis guarded.

The clinician's interpretation of the tracing should be communicated to the family and the pertinent discussions recorded in the case notes. Comment on the background of the tracing, upper and lower voltage limits of the bandwidth (in μV), whether sleep-wake cycling is present, and whether any seizures are noted along with their time and duration (see Table 2 for classification proposed by Hellström-Westas et al.^[3]).

East of England Neonatal Neuroprotection

2.9 FOR HOW LONG SHOULD aEEG MONITORING BE CONTINUED?

Monitoring should be continued until:

- the background recording has become stable for 24 hours
- there have been no seizures or stroke for 12–24 hours
- rewarming has been completed for infants receiving therapeutic cooling as this is a period associated with re-emergence of seizures.

All infants having cerebral function monitoring should have a formal EEG performed. The timing and frequency of the EEG will depend on the condition of the infant and resources available. However, an EEG on day 4 (after rewarming) in infants who have been cooled will provide the most useful prognostic information.

East of England Neonatal Neuroprotection

3. RATIONALE FOR THE RECOMMENDATIONS

Newborn infants admitted to the NICU have long had routine continuous monitoring of their heart rates, respiratory rates, O₂ saturations and blood pressure. Yet remarkably only in recent years has it been considered important to monitor neonatal brain function routinely using continuous EEG. Neurological status and development is of major concern to both parents and clinicians, and the improvement of long-term neurodevelopmental outcome has rightly become one of the major goals of modern neonatology. These concerns have emphasized the need for tools to detect and quantify brain injury, as a means of assisting clinical decision making as well as predicting long-term outcome. Obtainment of aEEG traces through continuous CFM monitoring provides very useful information about the functional integrity of the brain. CFM monitoring can be commenced immediately after an infant is admitted to the NICU.

Close surveillance of brain function at the bedside is now readily achievable with modern cerebral function monitors. These have been designed for continuous use in the NICU environment, and allow clinicians to monitor and record real-time neurological information 24 hours per day. The CFM will detect changes and abnormalities in cerebral function. It will assist clinicians in the direction of care on a day-to-day basis as well as highlight the need for neuroimaging and clinical intervention.

As well as indicating overall brain status, the CFM recording will also clearly indicate seizures, which are one of the main signs of cerebral dysfunction in neonates. Seizure activity has often been monitored by clinical assessment alone. However, a large proportion of seizure activity is either difficult to assess by clinical examination or has no clinical manifestation (“electro-clinical dissociation”). Bedside monitoring with aEEG traces can be used to identify seizure-like events in real time, with review of the raw EEG trace recommended for event validation. aEEG monitoring can also be used to observe the effects of anticonvulsants. The CFM can therefore play a useful role in the management of anticonvulsant therapy and assessment of their effectiveness.

When used in conjunction with other clinical data, and in combination with traditional neurological assessment, the CFM is a unique and powerful tool to aid in the assessment and management of infants at risk of brain injury in the NICU.

3. 1 aEEG AND ASSOCIATION WITH NEURODEVELOPMENTAL OUTCOME

Many studies have now evaluated the prognostic accuracy of early cerebral function monitoring in encephalopathic infants. aEEG patterns in the first days of life have been shown to correlate well with later neurodevelopmental outcome. Very abnormal traces in the first 6 hours after birth define a group of infants at highest risk for poor outcome; infants who have burst-suppression, a persistent low voltage, or flat traces have a high risk for death or disability. Conversely infants who show continuous normal voltage or discontinuous normal voltage patterns (without seizures) in the first 6 hrs are likely to survive with little or no sequelae ^[3].

East of England Neonatal Neuroprotection

Table 3 *Abnormal aEEG background patterns and association with outcome (adapted from Hellström-Westas et al., 2006^[3])*

| Gestational Age (weeks) | Background Pattern | Outcome |
|-------------------------|---|---|
| <33 | Reduced continuity in first 7 days postnatal | Associated with large IVH; long term outcome not assessed |
| <33 | Burst Suppression, Low Voltage, or Flat Trace in first 48 h postnatal | Severe handicap/death in infants with IVH Grade 3 to 4 |
| ≥37 | Discontinuous | Normal outcome if present only within the first 6–12 following perinatal asphyxia |
| ≥37 | Low voltage | Abnormal outcome after perinatal asphyxia |
| ≥37 | Burst suppression | Abnormal outcome after perinatal asphyxia; some infants healthy if aEEG background becomes continuous within 12 to 24 h |
| ≥37 | Flat trace | Severely abnormal outcome (death or major handicap) after perinatal asphyxia |

IVH, intraventricular haemorrhage

Note: Presence of epileptic seizure activity is always abnormal at all gestational ages; Background activity, including sleep-wake cycling, may be depressed by medications.

3.2 USE OF CFM MONITORING TO REFINE PREDICTION OF PROGNOSIS IN HYPOXIC-ISCHAEMIC ENCEPHALOPATHY

In infants with moderate HIE clinically (Sarnat & Sarnat grade 2), a severely abnormal EEG does suggest a poor prognosis^[4]. However, spontaneous recovery of aEEG patterns that were severely abnormal in the first hours of life is not uncommon^[5] and such an early aEEG may reflect dysfunction that can resolve rather than permanent injury. In the study of van Rooij *et al.*^[6], a small group of infants (6/65=9%) with a severely abnormal aEEG background trace at <6 hrs of birth, achieved recovery to a continuous normal background pattern within the first 24 hours (61% of whom survived without, or with only mild, disability).

East of England Neonatal Neuroprotection

Table 4 provides a guide to the prognostic interpretation of aEEG in hypoxic ischaemic encephalopathy in the absence of antiepileptic medication ^{3,13,15}

| Age at interpretation | CFM tracing | Prognosis |
|-----------------------|--|---|
| 6 hours | Continuous with Sleep wake cycling | Good prognosis – Consider rewarming if child not encephalopathic |
| | Discontinuous | High chance of cerebral recovery and normal outcome if recovers by 12 hours |
| | Burst suppression | Risk of poor outcome. If normal by 12-24 hours chance of good outcome (61% mild or no disability) |
| | Low voltage/Flat trace | Severely abnormal outcome |
| 48 hours | Continuous with SWC by 36 hours | High probability of good outcome 97% if clinically moderate encephalopathy 91% if mod- severe encephalopathy 75% if clinically severe encephalopathy |
| | Burst suppression Flat trace Low voltage | High probability of severe neurodevelopmental impairment or death 73% if clinically moderate encephalopathy 89% if moderate- severe encephalopathy 96% if clinically severe encephalopathy |

3.3 ROLE OF aEEG IN THERAPEUTIC HYPOTHERMIA

The BAPM guideline issued in 2020 recommends the routine use of therapeutic hypothermia in infants with moderate or severe encephalopathy secondary to hypoxic ischaemic brain injury^[7]. Prompt use of CFM in infants who have suffered significant perinatal distress or insult facilitates early identification of infants most likely to benefit from therapeutic hypothermia.

Whilst severe hypothermia can depress aEEG voltages, studies in animal models have confirmed that hypothermia in the therapeutic range has no effect on the upper and lower margins of aEEG readings^[8]. Of note, however, hypothermia does appear to delay the onset of sleep wake cycling and increase the time taken for the aEEG to recover^[9]. This may be because of prolongation of the half-life of anticonvulsants during hypothermia therapy. It is therefore important to ensure that this delay in

East of England Neonatal Neuroprotection

recovery of aEEG during hypothermia is not used as a basis of communicating a poor prognosis to parents.

3.4 NOTE ON COMPARISON OF aEEG WITH STANDARD 12-LEAD EEG

Advantages of CFM compared with standard EEG are that CFM monitoring is more easily applicable and available, especially during the night-time and out of hours, and is especially suitable for continuous monitoring because it is not limited to being a relatively brief “snapshot” in time. CFM is a reliable tool for monitoring both background patterns (especially normal and severely abnormal) and ictal activity, and aEEG recordings correlate well with formal full EEG findings^[10]. Certain focal, low amplitude, and very short periods of seizure discharges (<30 seconds) can be missed on the CFM however^[10]. Owing to the nature of the single/dual channel recording, it is not surprising that very brief seizure activity, as well as focal seizure activity, may be missed. In the study of Toet *et al.* focal seizures were not identified by CFM in two of 10 children who were noted to have electrical discharges during the simultaneous aEEG-EEG recording^[10].

Thus, notwithstanding the utility of the CFM on the NICU, it is important to appreciate that aEEG lacks the sensitivity of a full 12-lead EEG monitor and therefore cannot, and should not replace a full lead EEG where the latter is indicated. Therefore, infants in whom aEEG recording is undertaken should generally also undergo a standard 12-lead EEG performed by the technicians of the Department of Clinical Neurophysiology.

4.ROLE OF CFM IN PRETERM INFANTS

Although aEEG has not been as extensively evaluated in preterm infants as in term infants aEEG may prove useful in some situations in this population.

Infants with IVH: Infants with large Grade 3 or 4 IVH. Infants with IVH show decreased continuity, lower voltage patterns and more seizures. However, the presence of burst suppression within the first 72 hours of life has been associated with death or neurodevelopmental impairment at 2 years (PPV 63%, NPV91%).¹⁴ The presence of bursts at <130/hr is associated with a worse prognosis than if the bursts are more than 135/hr.³ Therefore, the aEEG may be useful as an additional tool when considering redirection of care in the setting of large IVHs.

Infants with abnormal movements: preterm infants are at risk of seizures especially in the presence of IVH. The effect of antiepileptic medication on the developing brain has not been extensively studied therefore in the presence of abnormal movements the aEEG can help to confirm the diagnosis of seizures prior to starting antiepileptic medication

Post-haemorrhagic ventricular dilatation: Infants with PHVD have been shown to develop burst suppression and decreased continuity even before signs of increased intracranial pressure become apparent. In the majority these changes resolved upon drainage device placement. In this setting the presence of aEEG changes can support a decision that an infant with PHVD needs treatment.¹³

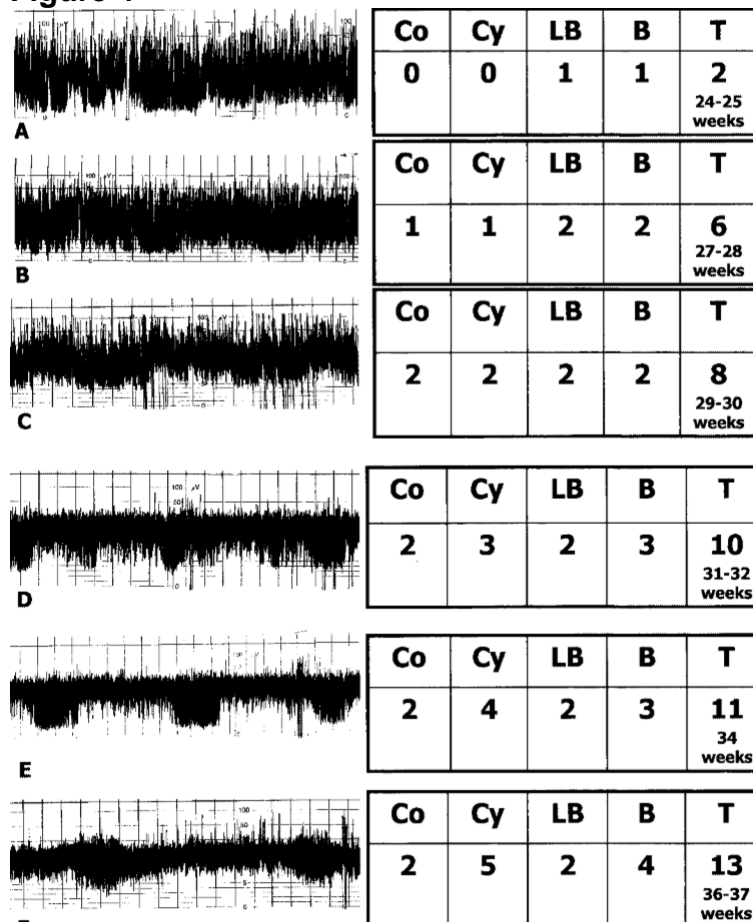
East of England Neonatal Neuroprotection

Sequential recordings: In vulnerable preterm infants, such as those with grade 3/4 IVH or hypoxic/inflammatory brain injury, short weekly recordings may provide information on continuing brain development and maturation of function. It has been shown that the continuity of an aEEG recording increases with gestational age in the preterm population without brain injury (See figure 4).¹⁶ This maturation can be a sign of healthy CNS development.¹⁷ It has also been noted that the presence of continuous background activity and sleep/wake cycles within the first postnatal week has been associated with a good neurodevelopmental outcome.¹⁸

Practical considerations: Electrode choice is important to maintain comfort and skin integrity. With this in mind hydrogel electrodes are recommended for use in preterm infants with mature skin and should be gently removed using adhesive remover wipes (Appeel). Disc electrodes can be used for infants with immature skin however care should be taken to monitor skin integrity regularly. The use of subdermal needles is strongly discouraged for this population of infants.

Although more research is needed in this area, dysmaturity (or no maturation) may be a sign of brain injury and altered brain function. This may be useful in determining if an infant is likely to have poor neurodevelopmental outcome, or at the very least help you to identify the most vulnerable preterm infants.

Figure 4



The left side of the table demonstrates a progressive series of CFM monitor recordings; the right side shows the component maturation score values for the respective traces. There is a maturation of the tracings from A through F in these recordings. Postconceptional age ranges are indicated. Co, continuity of the recording; Cy, presence of cycling; LB, lower border amplitude score; B, bandwidth; T, total score.

East of England Neonatal Neuroprotection

5. REFERENCES

- [1] al Naqeeb N, Edwards AD, Cowan FM, Azzopardi D. Assessment of neonatal encephalopathy by amplitude-integrated electroencephalography. *Pediatrics* 1999;**103**:1263-71.
- [2] Toet MC, Hellström-Westas L, Groenendaal F, Eken P, de Vries LS. Amplitude integrated EEG 3 and 6 hours after birth in full term neonates with hypoxic-ischaemic encephalopathy. *Arch Dis Child Fetal Neonatal Ed.* 1999;**81**:F19-23.
- [3] Hellström-Westas, L, Rosén, I, de Vries LS, Greisen G. Amplitude-integrated EEG Classification and Interpretation in Preterm and Term Infants. *Neoreviews* 2006;**7**: e76-e87.
- [4] Allan WC. The clinical spectrum and prediction of outcome in hypoxic-ischaemic encephalopathy. *NeoReviews*. 2002;**3**:e108-15.
- [5] ter Horst HJ, Sommer C, Bergman KA, Fock JM, van Weerden TW, Bos AF. Prognostic significance of amplitude-integrated EEG during the first 72 hours after birth in severely asphyxiated neonates. *Pediatr Res.* 2004;**55**:1026-33.
- [6] van Rooij LG, Toet MC, Osredkar D, van Huffelen AC, Groenendaal F, de Vries LS. Recovery of amplitude integrated electroencephalographic background patterns within 24 hours of perinatal asphyxia. *Arch Dis Child Fetal Neonatal Ed.* 2005;**90**:F245-51.
- [7] BAPM: *Therapeutic Hypothermia for Neonatal Encephalopathy A Framework for Practice: guidance*. Issued November 2020 https://hubble-live-assets.s3.amazonaws.com/bapm/file_asset/file/10/TH_document_for_publication.pdf
- [8] Thoresen M. Supportive care during neuroprotective hypothermia in the term newborn: adverse effects and their prevention. *Clin Perinatol.* 2008;**35**:749-63.
- [9] Thoresen M, Hellström-Westas L, Liu X, de Vries LS. Effect of hypothermia on amplitude-integrated electroencephalogram in infants with asphyxia. *Pediatrics.* 2010;**126**:e131-9.
- [10] Toet MC, van der Meij W, de Vries LS, Uiterwaal CS, van Huffelen KC. Comparison between simultaneously recorded amplitude integrated electroencephalogram (cerebral function monitor) and standard electroencephalogram in neonates. *Pediatrics* 2002;**109**:772-9.
- [11] Levene MI, Sands C, Grindulis H, Moore JR. Comparison of two methods of predicting outcome in perinatal asphyxia. *Lancet* 1986;**8472**:67-9.

East of England Neonatal Neuroprotection

- [12] Sarnat HB, Sarnat MS. Neonatal encephalopathy following fetal distress. A clinical and electroencephalographic study. *Arch Neurol.* 1976;**33**:696-705.
- [13] Tao JD and Mathur AM. Using amplitude integrated EEG in Neonatal intensive care. *Journal of Perinatology* 2010(30) S73-S81
- [14] Hart AR, Ponussamy A et al. Neonatal Cerebral Function Monitoring – Understanding the amplitude integrated EEG. *Paediatrics and child health* 2016 <http://dx.doi.org/10.1016/i.paed.2016.11.006>
- [15] Xiqo-Juan Y, Wei W et al. Value of early amplitude integrated EEG in early diagnosis and prognosis prediction of neonatal hypoxic ischaemic encephalopathy. *Int J Clin Exp Med* 2014;7(4):1099-1104
- [16] Burdjalov VF, Baumgart S. CFM: A new scoring system for the evaluation of brain maturation in neonates. *Pediatrics* 2003 112(4): 855-861
- [17] Zhang D, Liu Y et al. Reference values for amplitude integrated EEGs in infants from preterm to 3.5 months of age. *Paediatrics* 2011;127:e1280-7
- [18] Hellstrom Westas L, Rosen I et al. Cerebral function monitoring in extremely small low birthweight infants during the first week of life. *Neuropediatrics* 1991;22:27-32

Other source documents

- Hellström-Westas L, de Vries LS, & Rosen, editors. An Atlas of Amplitude-Integrated EEGs in the Newborn. 1st ed. London: Parthenon; 2003.
- De Vries LS, Hellström-Westas L. Role of cerebral function monitoring in the newborn. *Arch Dis Child Fetal Neonatal Ed.* 2005 May;90(3):F201-7.

Glossary

| | |
|------|---|
| aEEG | Amplitude-integrated electroencephalogram |
| CFM | Cerebral Function Monitor |
| HIE | Hypoxic-ischaemic encephalopathy |

East of England Neonatal Neuroprotection

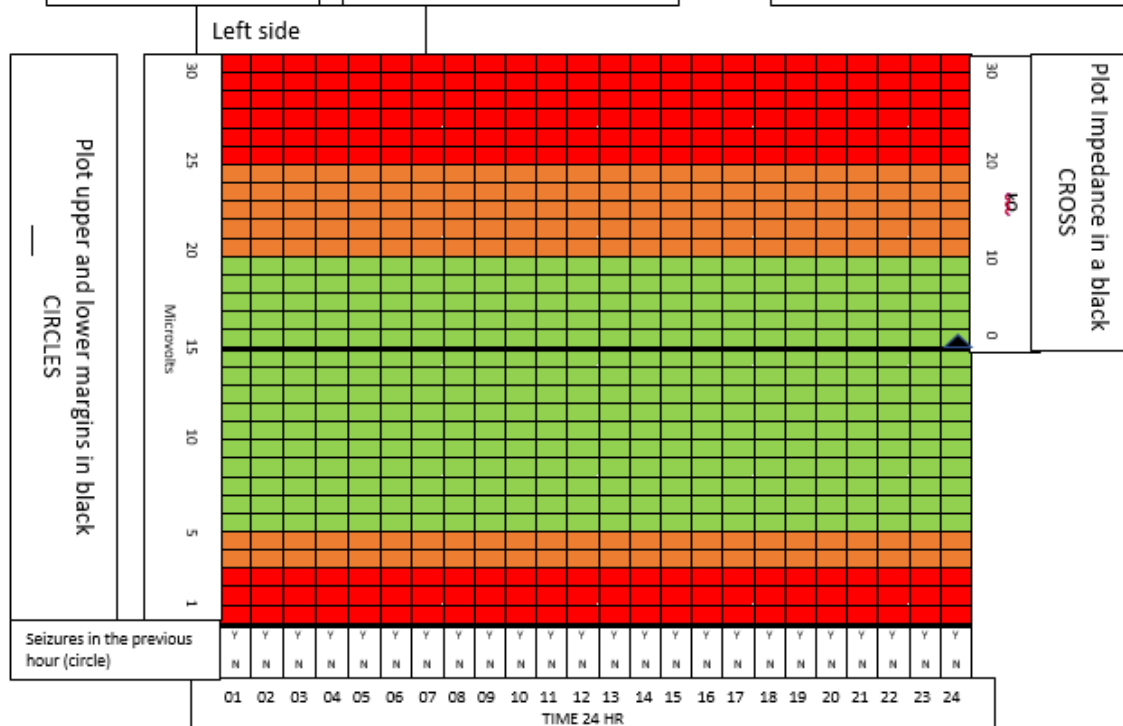
Intraventricular haemorrhage

IVH

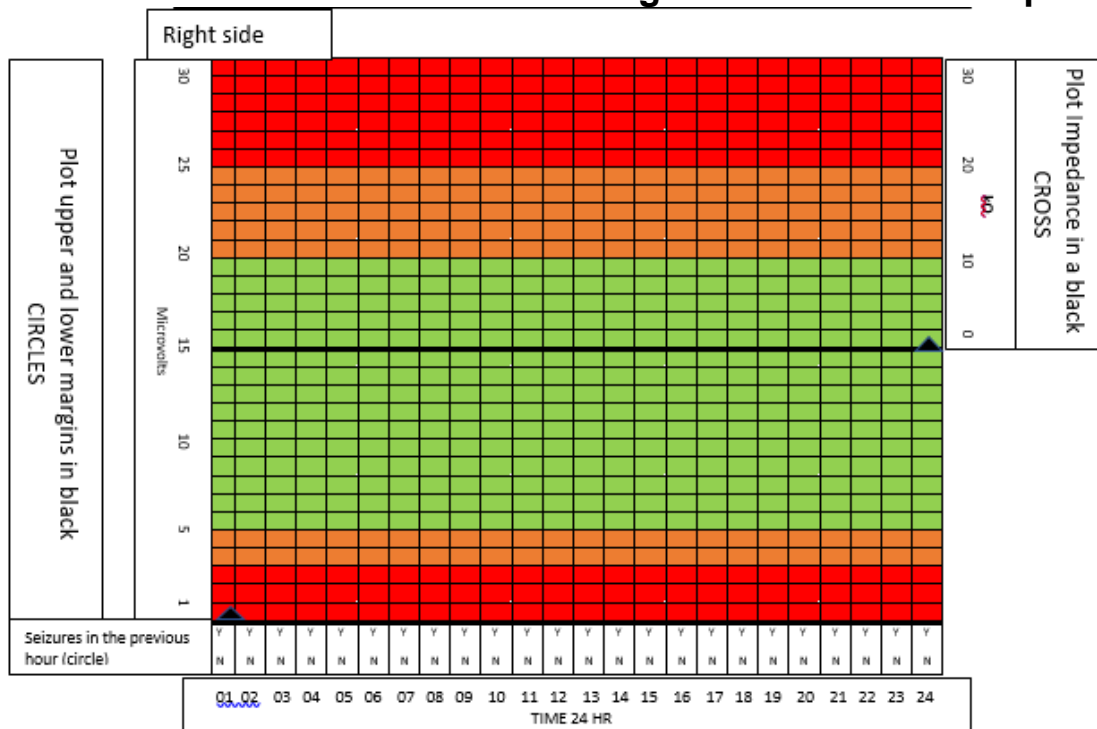
APPENDIX 1- CEREBRAL FUNCTION MONITORING OBSERVATION CHART

CFM observation chart Date _____

| | | |
|--|--|----------------------|
| <p>Observe baby for Abnormal movements</p> <p>Observe CFM for Significant changes in pattern Changes in pattern during abnormal movements Seizures</p> | <p>Mark event on CFM Any handling of baby Abnormal movements</p> <p>Inform doctor if Significant change in limits/ impedance Limits or impedance in amber or red zone Any abnormal movements by baby</p> | <p>Patient label</p> |
|--|--|----------------------|



East of England Neonatal Neuroprotection



APPENDIX 2- CEREBRAL FUNCTION MONITORING CLINICAL COMPETENCY CHECKLIST

East of England Neonatal Neuroprotection

Competency: Cerebral Function Monitoring

The cerebral function monitor (CFM) is used to monitor the brain wave pattern of infants who are identified as having a risk for brain injury and/or seizures.

CFM can be applied quickly in the clinical setting, and offers significant information which helps guide the treatments, management and progress of affected neonates.

| Competency | Date | Staff sign | Consultant/Lead Nurse/PDN/Link Nurse sign |
|--|------|------------|---|
| 1) Identify babies where CFM monitoring should be considered <ul style="list-style-type: none"> - Poor condition at birth - Therapeutic hypothermia - Abnormal movements - Intracranial haemorrhage - Term / preterm* | | | |
| 2) Identify where the CFM machine and consumables are allocated | | | |
| 3) Recognise appropriate placement of CFM needles/cups <ul style="list-style-type: none"> - Measurements look appropriate - Needles well secured and covered - Good contact tracing on the CFM - Low impedance | | | |
| 4) Understand rationale behind hourly CFM monitoring | | | |
| 5) Create and label events on the CFM machine including <ul style="list-style-type: none"> - cares / significant handling - clinical seizures/abnormal movements - anticonvulsant medications | | | |
| 6) Know cut offs for normal upper and lower margins, describe sleep wake cycling and recognise changes in limits during seizures | | | |
| 7) Know how to check for impedance levels and record them on CFM observation chart | | | |
| 8) Understand the documentation for completion when CFM monitoring is in place | | | |
| 9) Know when to escalate for medical review | | | |
| 10) Be able to <ul style="list-style-type: none"> - start recording - suspend/restart monitoring - stop recording | | | |
| 11) Able to clean equipment after use | | | |

East of England Neonatal Neuroprotection

| Extended competencies | Date | Staff sign | |
|--|------|------------|--|
| 12) Be able to start CFM machine and enter patient details | | | |
| 13) Measure and insert CFM needles <ul style="list-style-type: none"> - Gather correct equipment - Appropriate hand hygiene - Measure and mark head correctly - Insert needles appropriately - Secure needles and connect - Ensure good quality tracing - Document in notes | | | |
| 14) Identify background patterns of CFM <ul style="list-style-type: none"> - Continuous Normal Voltage - Discontinuous Normal Voltage - Burst Suppression - Continuous Low Voltage - Flat trace | | | |

East of England Neonatal Neuroprotection

APPENDIX 3- CEREBRAL FUNCTION MONITORING REPORTING SHEET

To be completed by Medical team 1 hour after application of CFM to establish a baseline, at 6 hours, 24,48,72 hours, prior to removing CFM or when a nurse escalates for medical team to review.

| | |
|---|--|
| Indication for medical aEEG reporting (Routine, Changes in aEEG baseline, changes in baby's condition), seizures (suspected or confirmed –clinical or electrographic), limits within amber or red zone. | |
| | |
| Medication (nb anticonvulsants including time given) | |
| | |
| Report See CFM Guidelines for description of patterns | |
| Date and Time Period | |
| Impedance | |
| Artefact? | |
| Lower Margin μ V | |
| Upper Margin μ V | |
| Background Continuous Discontinuous Burst Suppression | |
| Sleep-Wake Cycling Present Imminent/Immature Absent | |
| Seizure Isolated Repetitive Status epilepticus | |
| EEG Yes No | |
| Comments | |
| | |


East of England Neonatal Neuroprotection

| | | | |
|---------------|--|-------------|--|
| Signed | | Date | |
|---------------|--|-------------|--|

Patient details

Printed sections from the CFM trace can be stuck in below

East of England Neonatal Neuroprotection



East of England Neonatal Neuroprotection

References

All Rights Reserved. The East of England Neonatal ODN withholds all rights to the maximum extent allowable under law. Any unauthorised broadcasting, public performance, copying or re-recording will constitute infringement of copyright. Any reproduction must be authorised and consulted with by the holding organisation (East of England Neonatal ODN).

The organisation is open to share the document for supporting or reference purposes but appropriate authorisation and discussion must take place to ensure any clinical risk is mitigated. The document must not incur alteration that may pose patients at potential risk. The East of England Neonatal ODN accepts no legal responsibility against any unlawful reproduction. The document only applies to the East of England region with due process followed in agreeing the content.

East of England Neonatal Neuroprotection Exceptional Circumstances Form

Form to be completed in the **exceptional** circumstances that the Trust is not able to follow ODN approved guidelines.

| | |
|--|--|
| Details of person completing the form: | |
| Title: | Organisation: |
| First name: | Email contact address: |
| Surname: | Telephone contact number: |
| Title of document to be excepted from: | |
| Rationale why Trust is unable to adhere to the document: | |
| Signature of speciality Clinical Lead: | Signature of Trust Nursing / Medical Director: |
| Date: | Date: |
| Hard Copy Received by ODN (date and sign): | Date acknowledgement receipt sent out: |

Please email form to: mandybaker6@nhs.net requesting receipt.

Send hard signed copy to: Mandy Baker
EOE ODN Executive Administrator
Box 93
Cambridge University Hospital
Hills Road
Cambridge CB2 0QQ